

OCT and OCT Angiography

Real World Case Studies for Enhanced Interpretation

Greg Caldwell OD, FAAO
 Carolyn Majcher, OD, FAAO
 Vision Expo
 Thursday, March 12, 2026




1

On behalf of Vision Expo, we sincerely thank you for being with us this year.

Reminder to Complete Your Session Evaluations!

Please be sure to complete your digital session evaluations for each course you attended! Your feedback is important to us as our Education Planning Committee considers content and speakers for future meetings to provide you with the best education possible.



2

Contact:

- majcher@nsuok.edu
- 918-444-4155

Disclosures:

- Paid consultant/speaker for:
 - Carl Zeiss Meditec
 - Astellas (Iveric bio)
 - Apellis
 - Regeneron Pharmaceuticals
 - Optomed
- Paid advisory board member for Apellis Pharmaceuticals, LENZ Therapeutics, Notal Vision, Topcon, Tarsus, Genentech


All financial relationships have been mitigated



3

Disclosures- Greg Caldwell, OD, FAAO
All relevant relationships have been mitigated

- ** Lectured for: Alcon, B&L, Dompé, Lenz
- ** Disclosure: Receive speaker honorariums
- ** Advisory Board: Dompé, Envision, Tarsus
- ** Disclosure: Receive participant honorariums
- ** I have no direct financial or proprietary interest in any companies, products or services mentioned in this presentation
- ** Disclosure: Non-related financial affiliation with Pharamex
- ** Healthcare Registries – Chairman of Advisory Council for Diabetes and AMD
- ** The content of this activity was prepared independently by me - Dr. Caldwell
- ** The content and format of this course is presented without commercial bias and does not claim superiority of any commercial product or service
- ** Optometric Education Consultants – Scottsdale, AZ, Pittsburgh, PA, Sarasota, FL, Amsterdamm, Orlando, FL, Mackinac Island, MI, Quebec City, Canada, and Nashville, TN- Owner



4

My Practice

I am a clinician first then a scientist

- Some are scientists first then clinician
- I need to simplify for patient and patient care.
- Science is great, but not good if there isn't a clinical application.
- Some lectures are science based without clinical application.
- My lecture will be a hybrid. Showing clinical applications of the science

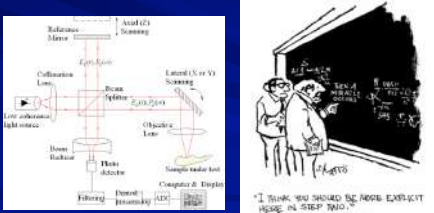


It is wonderful to have someone who's juggling so many aspects of optometry [scientific, clinical experience, teacher & lecturer]. It is refreshing and very informative. -Sarah

5

Optical Coherence Tomography

Course Design



"I THINK YOU SHOULD BE ABBE EMMERT
 BECAUSE HE SHEEP KNOW."

6

OCT and OCT Angiography

Both are Becoming Equally Important in Diagnosis, Management, and Treatment

7

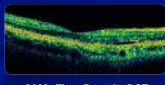
Optical Coherence Tomography

- ~ OCT is an optical signal acquisition and processing method
- ~ Time domain OCT
 - * 15-16 microns of resolution
 - * Stratus (Zeiss)
- ~ Spectral domain (SD-OCT) or Fourier domain OCT
 - * Spatially encoded frequency domain OCT (SEFD-OCT)
 - * 5-6 microns of resolution
 - o Able to see photoreceptor morphology (inner/outer segments)
 - * 50 times faster than time domain
- ~ Swept source OCT
 - * Time encoded frequency domain OCT
 - * 1 micron of resolution
- ~ Future of OCT- intraoperative imaging, blood flow and oxygenation measurements
- ~ May have the possibility to assess retinal pathology like a pathologist

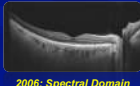
8

OCT Angiography: the Next Chapter in Posterior Imaging

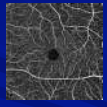
- ~ Images retinal microvasculature without dye injection
- ~ Displays structure and function from a single imaging system



2002: Time Domain OCT




2006: Spectral Domain OCT



2014: OCTA

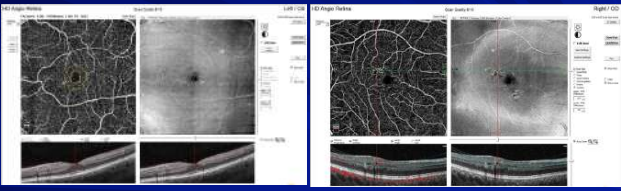
9

Inner Retina versus Outer Retina



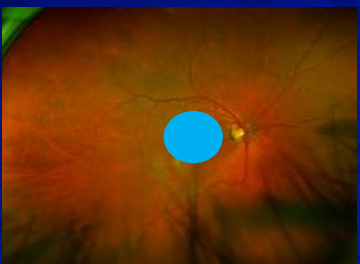
10

Diabetes

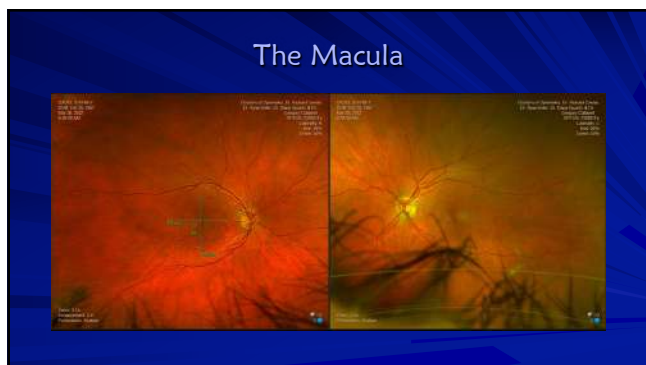


11

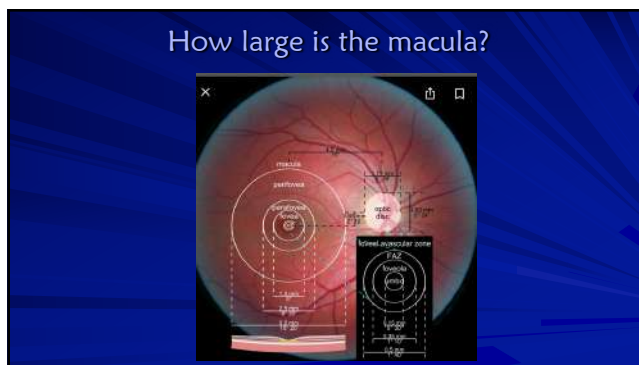
Where is the macula?



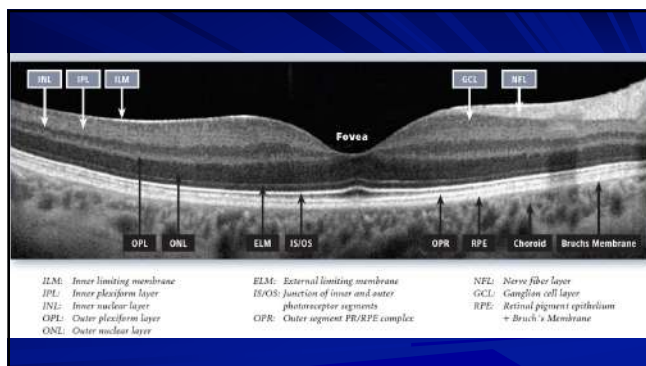
12



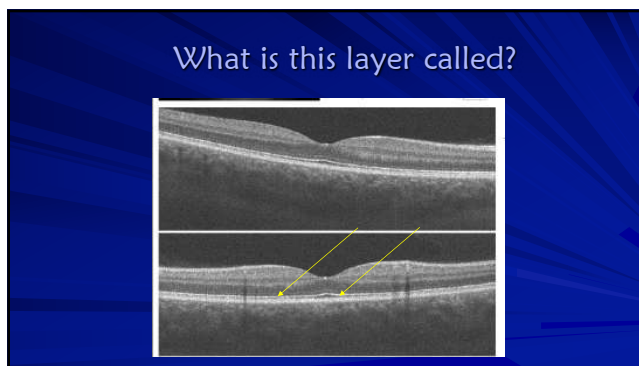
13



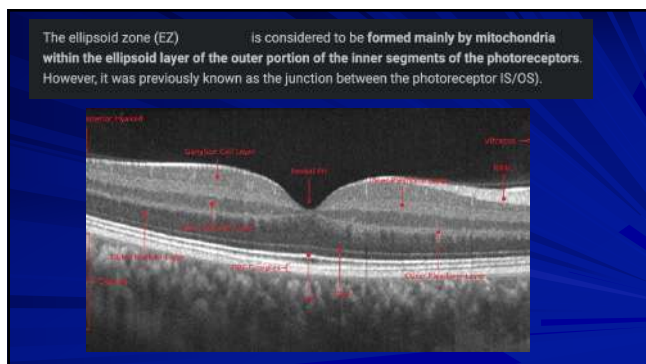
14



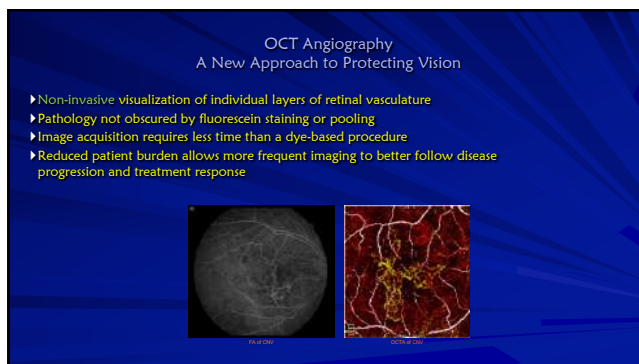
15



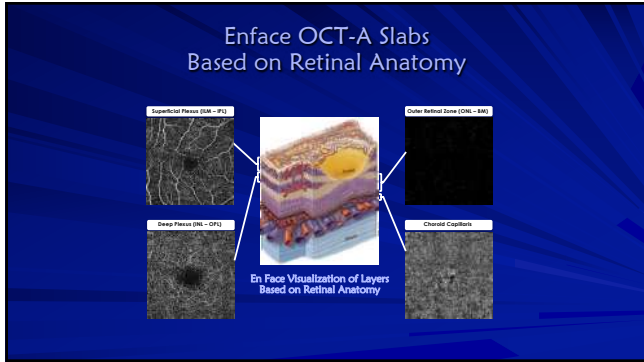
16



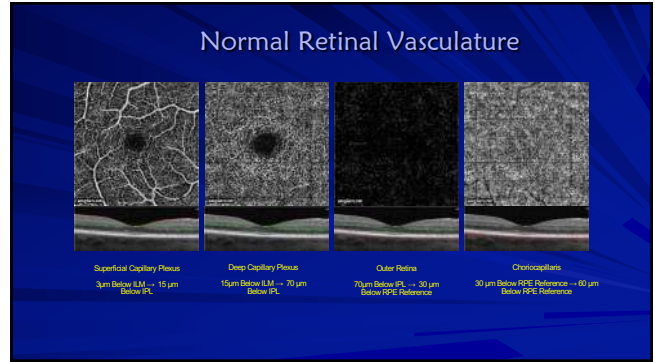
17



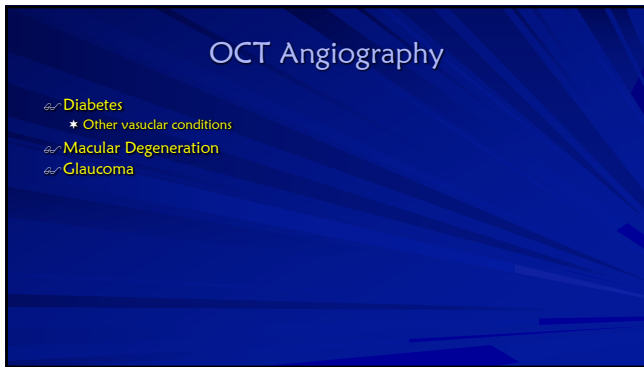
18



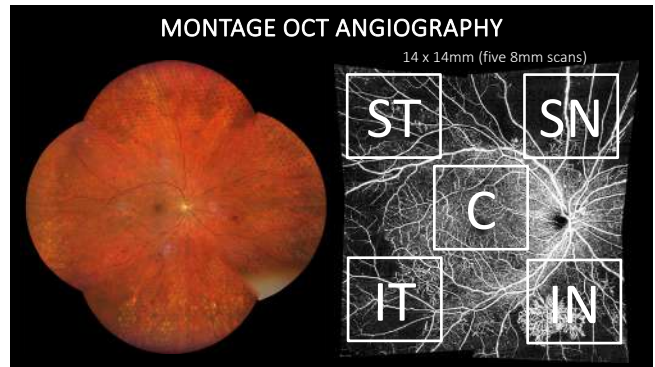
19



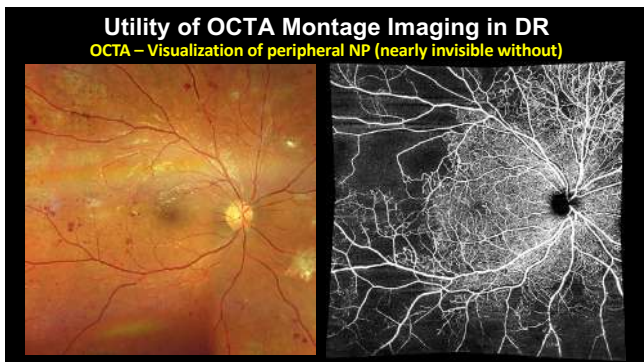
20



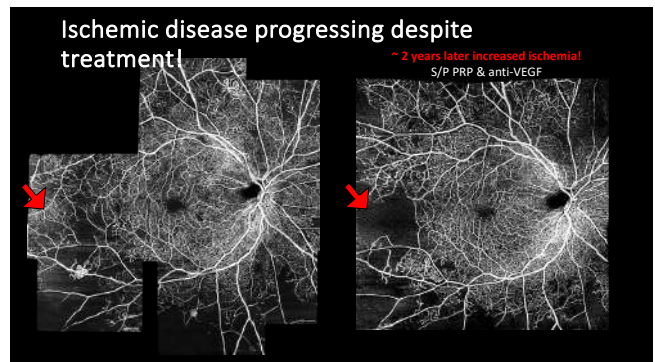
21



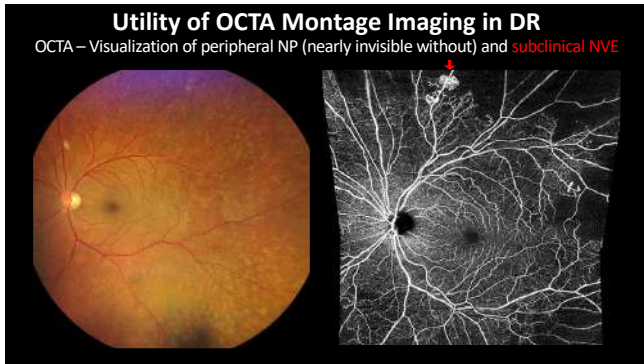
22



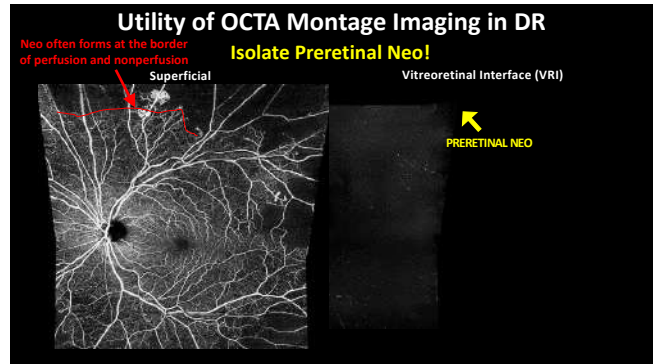
23



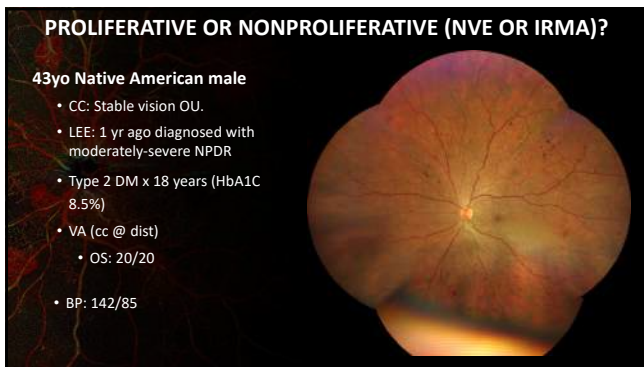
24



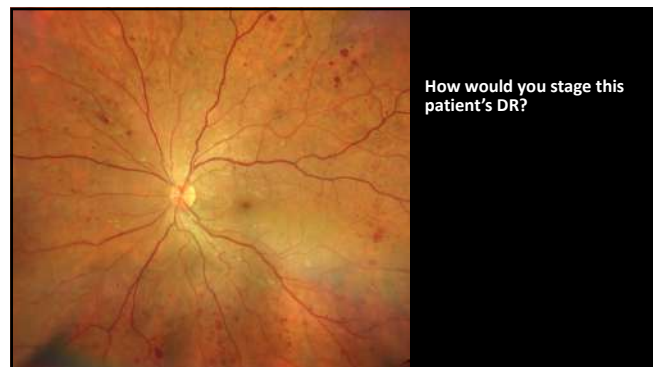
25



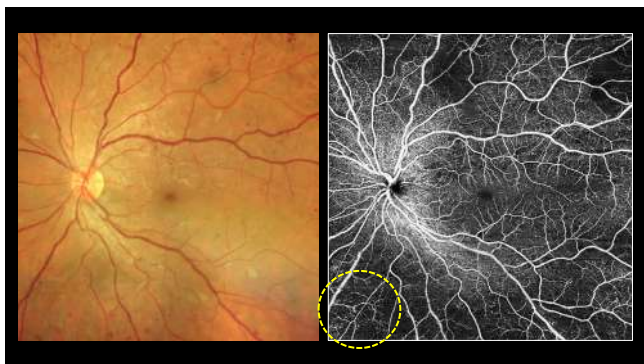
26



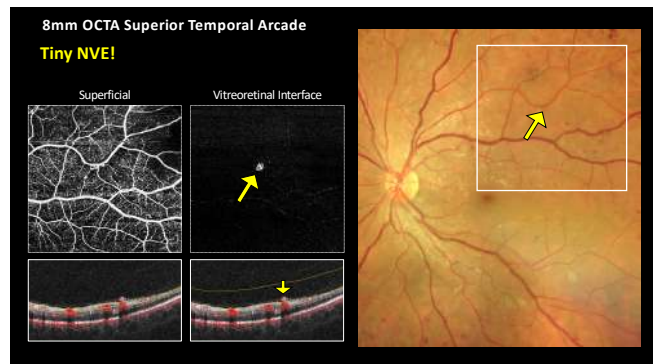
27



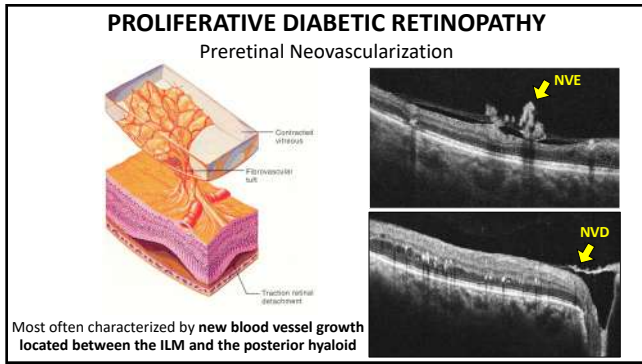
28



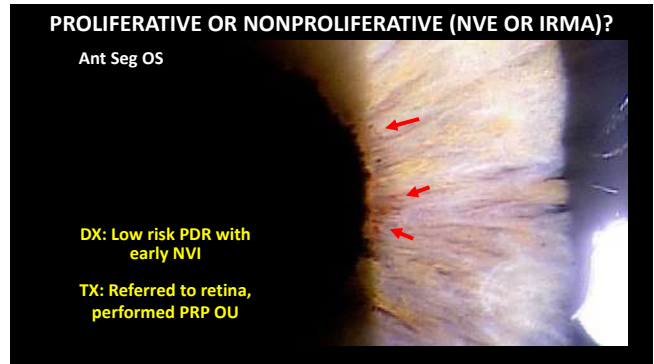
29



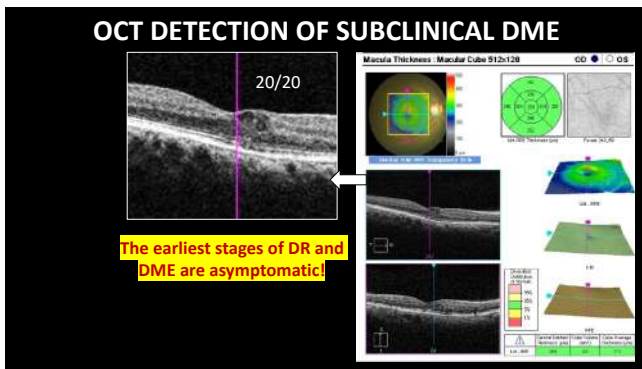
30



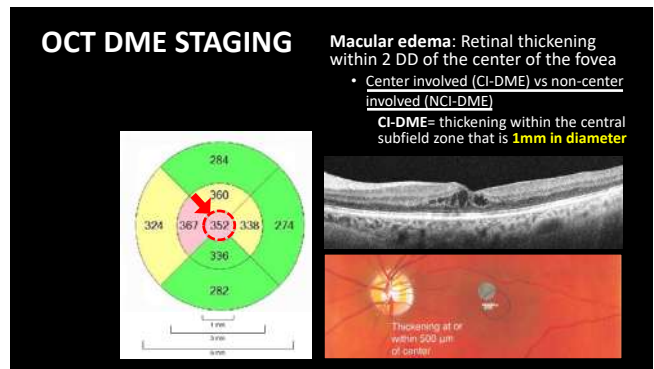
31



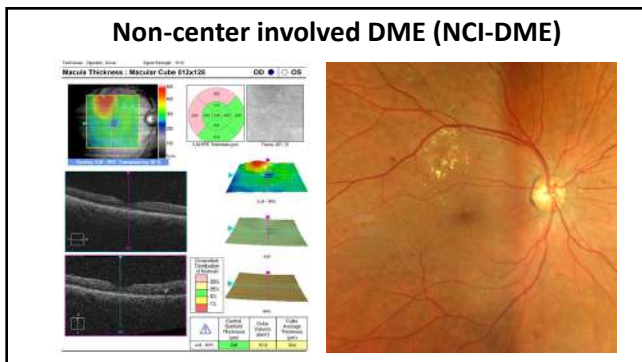
32



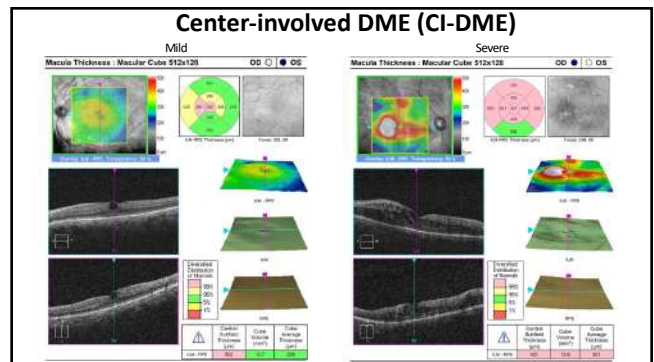
33



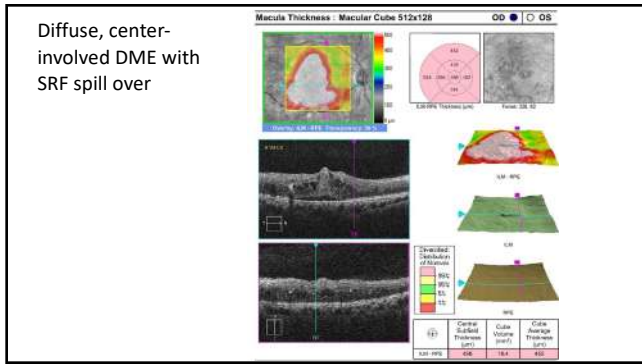
34



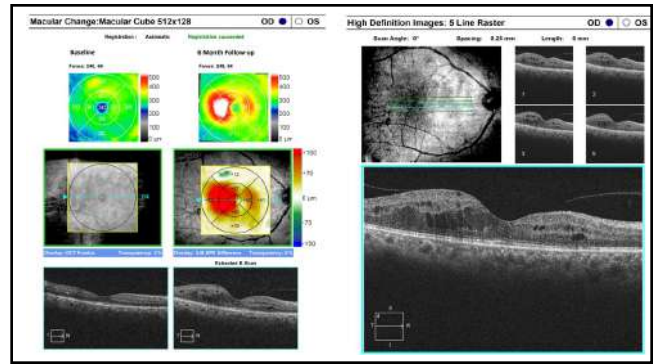
35



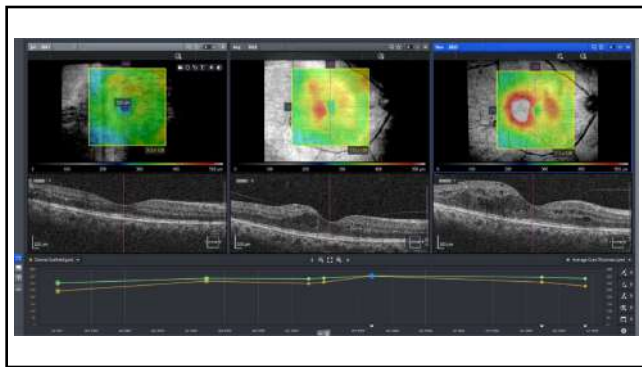
36



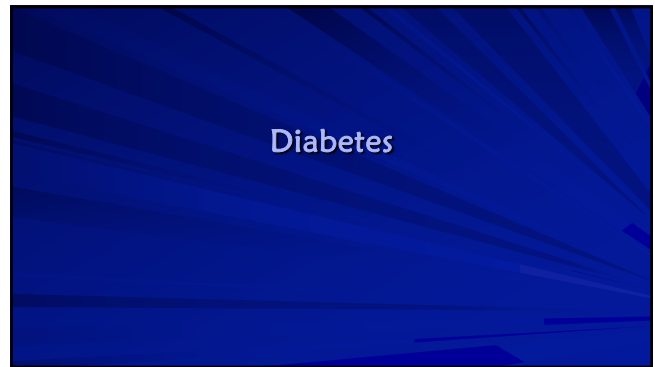
37



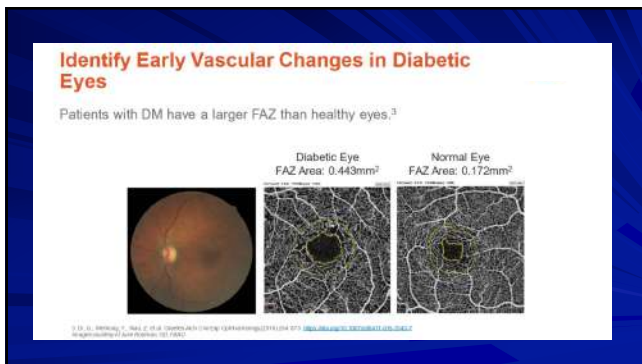
38



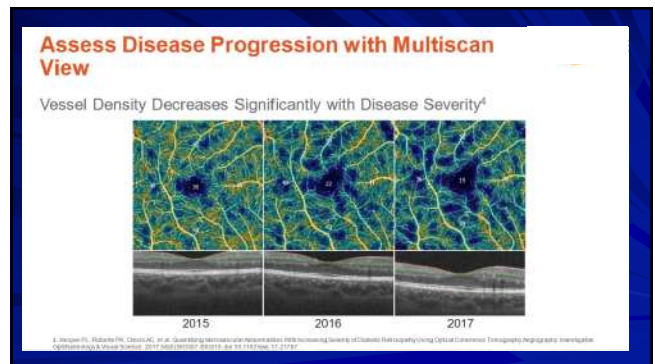
39



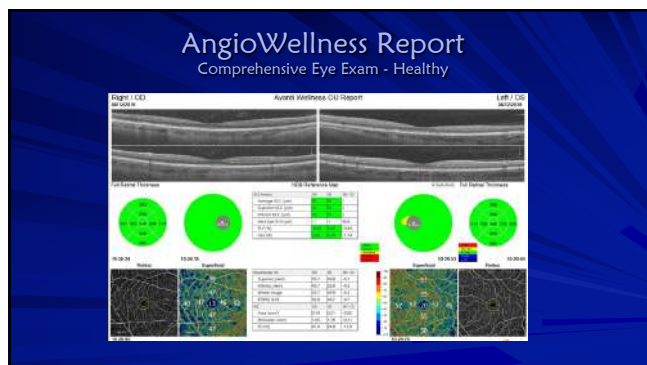
40



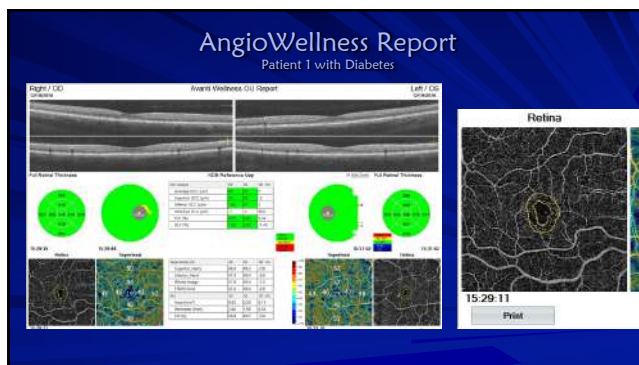
41




42



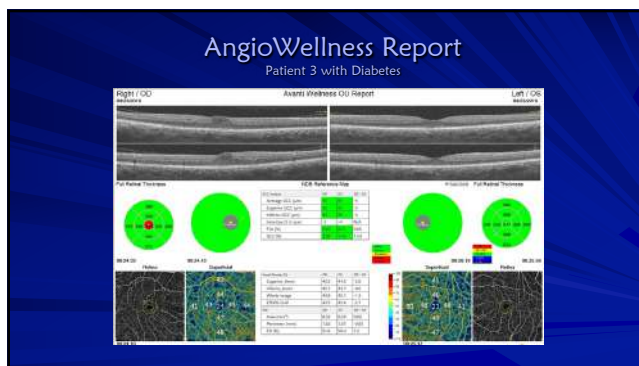
43



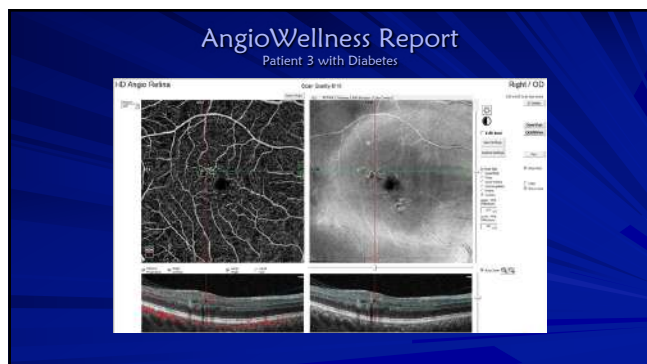
44



45



46

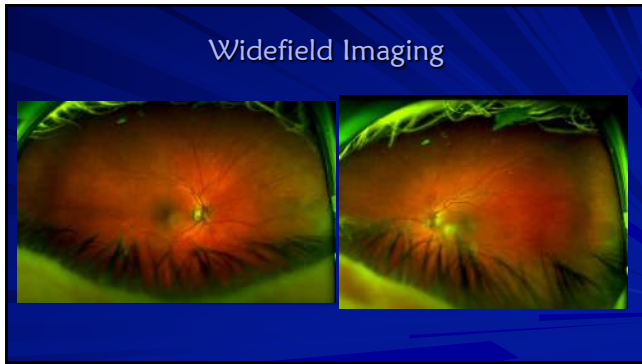


47

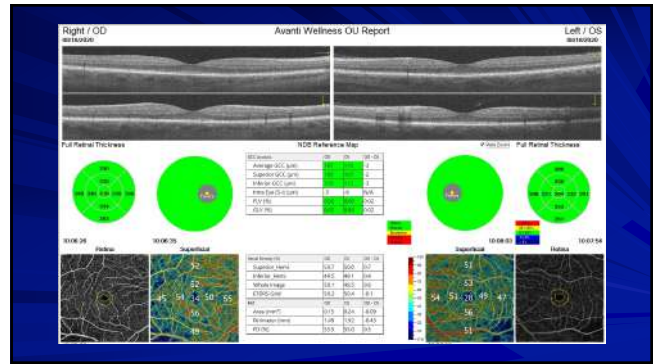
58-year-old man with diabetes

- New patient to the practice
- BS: unsure, last HbA1c unsure
- DM meds: metformin, glyburide, Invokana
- Vision 20/20
- Anterior segment: normal

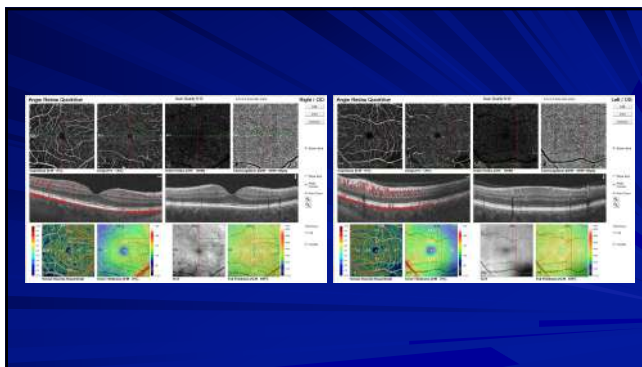
48



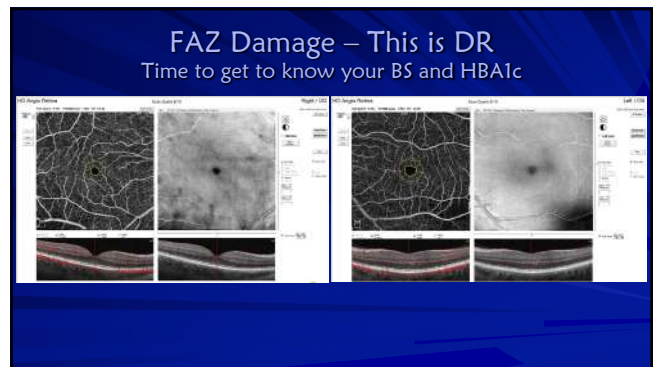49



50



51

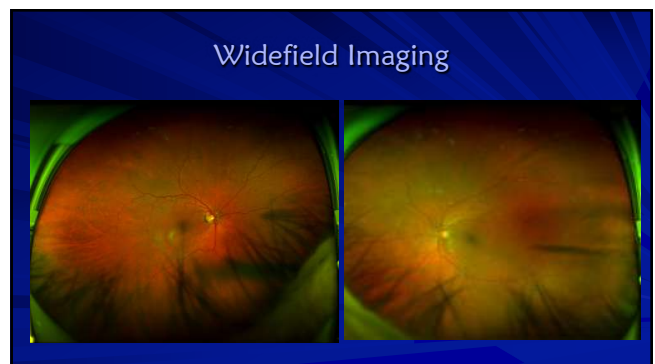

52

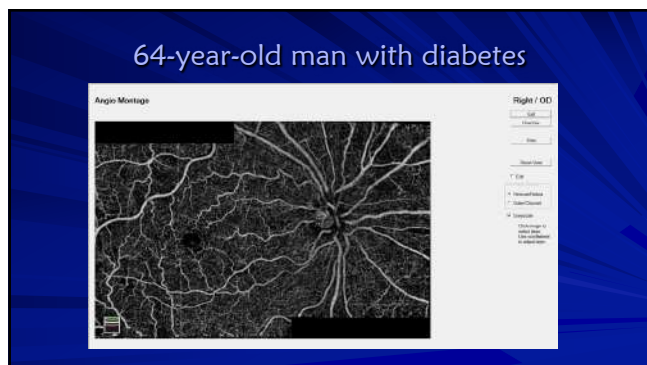64-year-old man with diabetes

- BS: 134 this AM, last HbA1c 8.0
- DM meds: Novolog and Amaryl
- Vision 20/20
- Anterior segment: normal

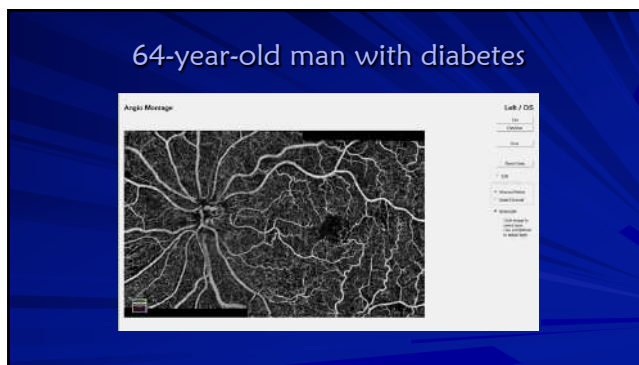
53



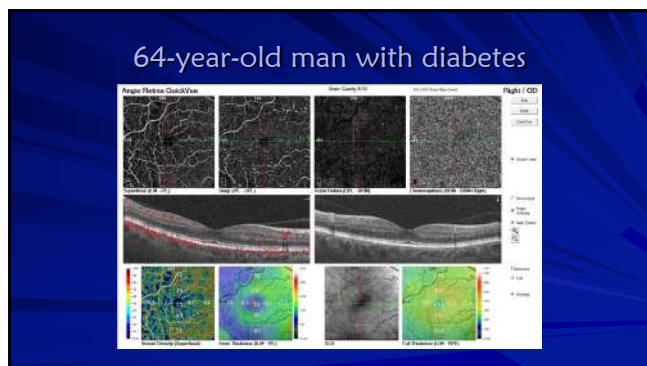
54



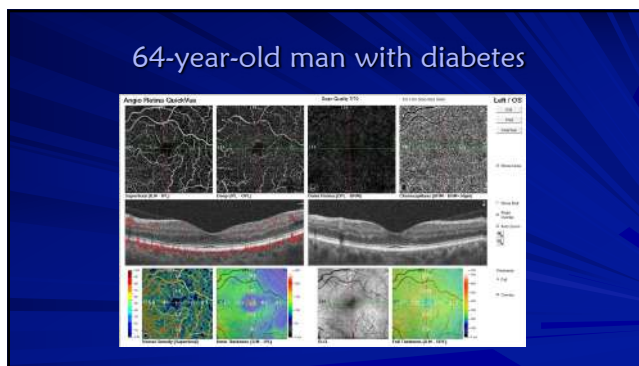
55



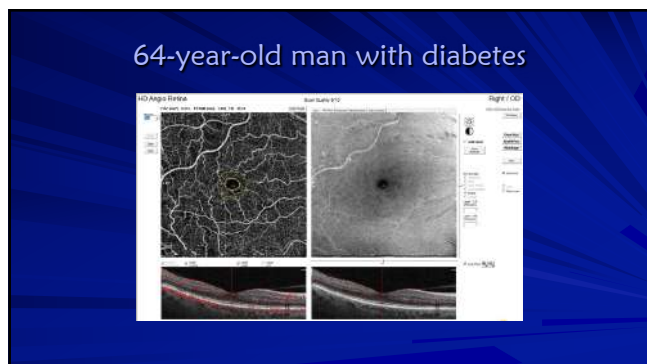56



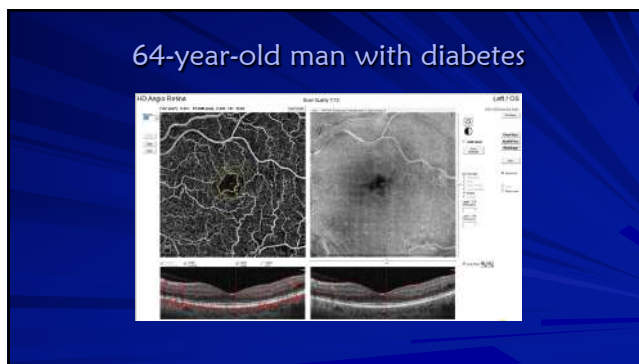57



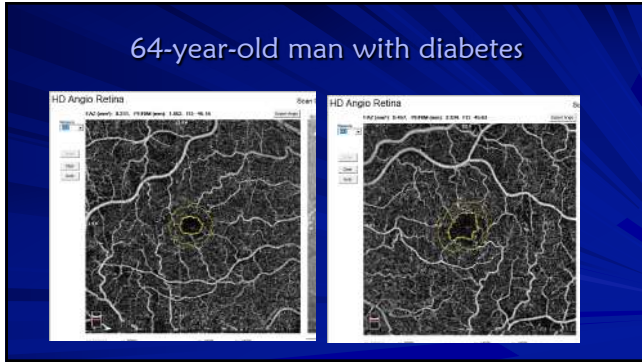58



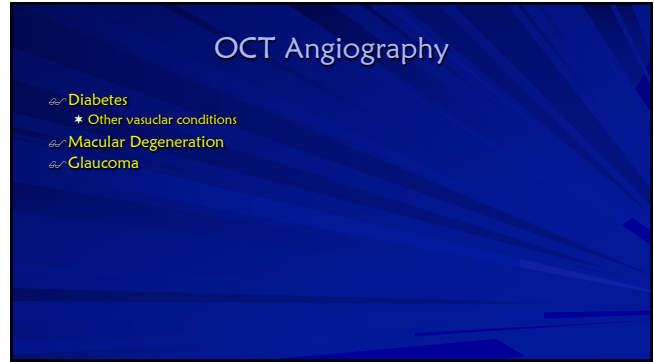
59



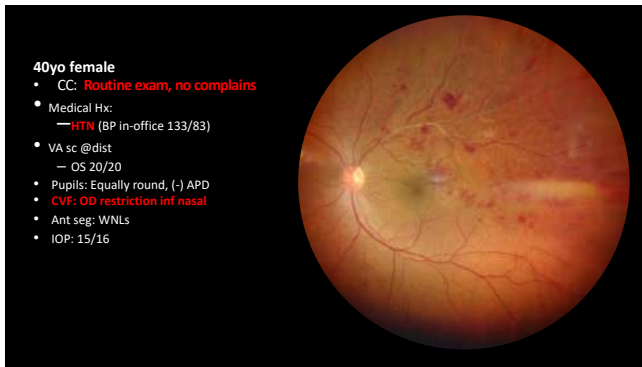
60



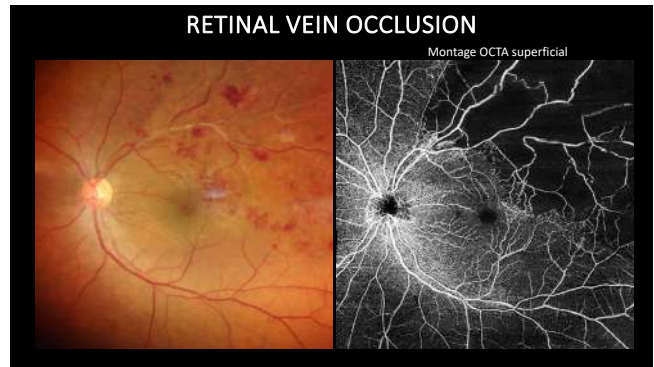
61



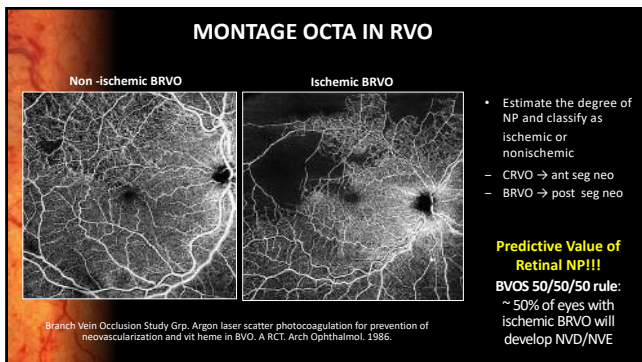
62



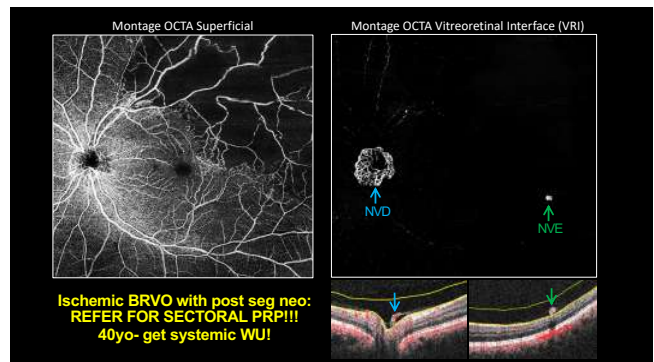
63



64



65




66

MORE THAN MACULAR EDEMA

57yo female

- CC: **Noted blur esp central & superior OS while driving**
- Medical Hx:
 - DM type 2 diagnosed 5 months ago
 - +ANA, migraines, arthritis, COVID 9 months ago
 - No HTN!
- VA sc @dist
 - OS CF, PHNI
- Pupils: Equally round, 3+ RAPD OS
- CVF: OS restriction superior
- Ant seg: WNLs & IOP: 17/18
- BP: 117/77





67

CRVO Classification

Features suggestive of ISCHEMIC CRVO

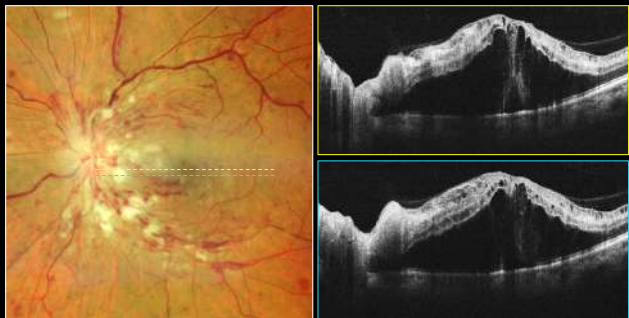
- ~50% of all CRVOs
- ≥ 10 DAs of NP via IVFA
- VA worse than 20/200
- Prominent RAPD
- Severe hemorrhaging and exudation

ISCHEMIC CRVO = 50-60% INCIDENCE OF ANT SEG NEO (MOST DEVELOP WITHIN 3-5 MONTHS)!!!

68

MORE THAN MACULAR EDEMA

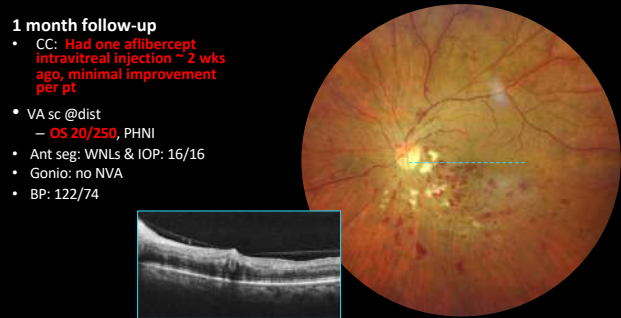


69

MORE THAN MACULAR EDEMA

1 month follow-up

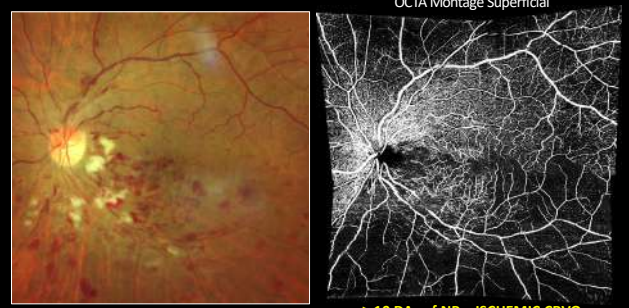
- CC: **Had one aflibercept intravitreal injection ~ 2 wks ago, minimal improvement per pt**
- VA sc @dist
 - OS 20/250, PHNI
- Ant seg: WNLs & IOP: 16/16
- Gonio: no NVA
- BP: 122/74



70

MORE THAN MACULAR EDEMA

OCTA Montage Superficial



≥ 10 DAs of NP = ISCHEMIC CRVO

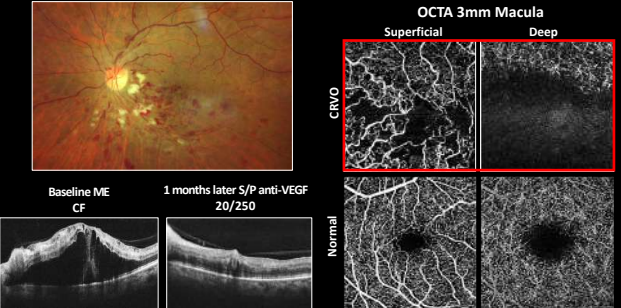
71

UTILITY OF OCTA IN RVO – MACULAR ISCHEMIA

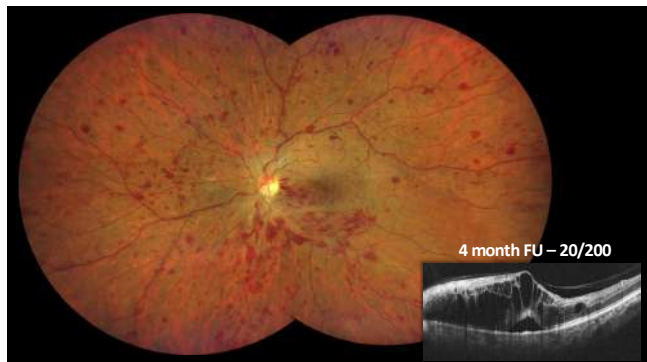
OCTA 3mm Macula

	Superficial	Deep
CRVO		
Normal		

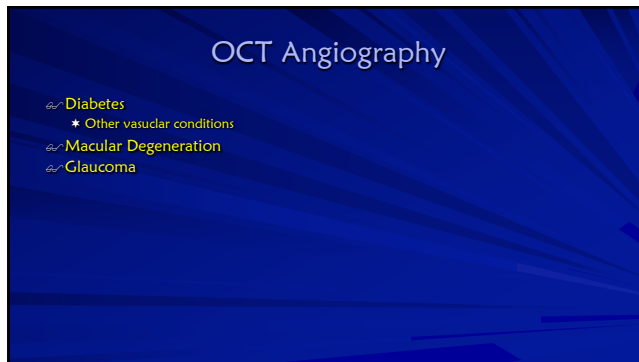
Baseline ME CF vs 1 months later S/P anti-VEGF 20/250



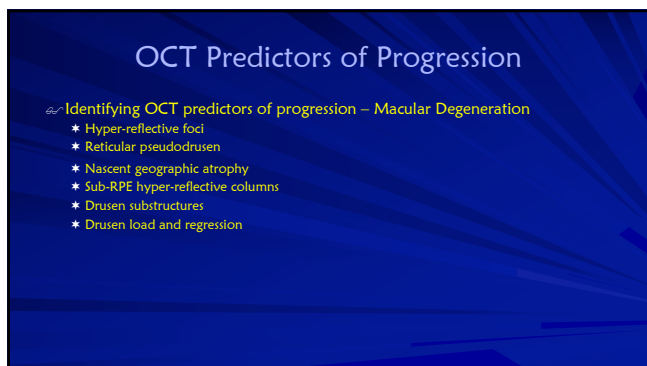
72



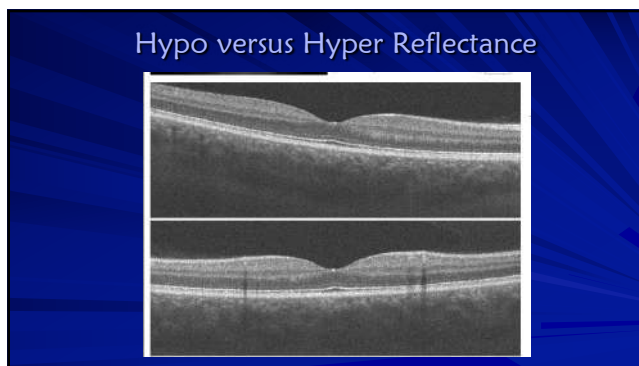
73



74



75



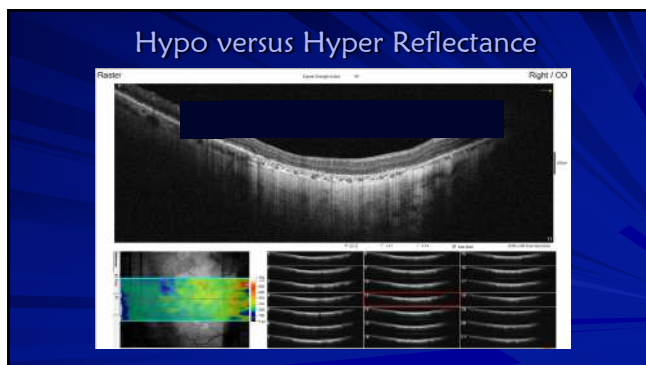
76



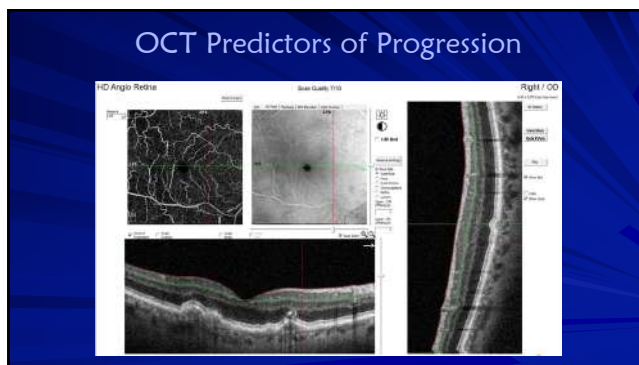
77



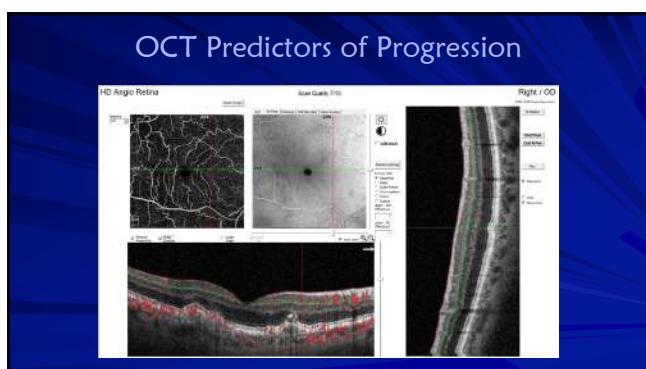
78



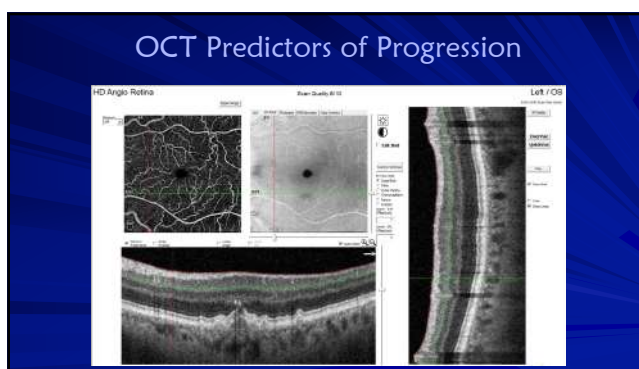
79



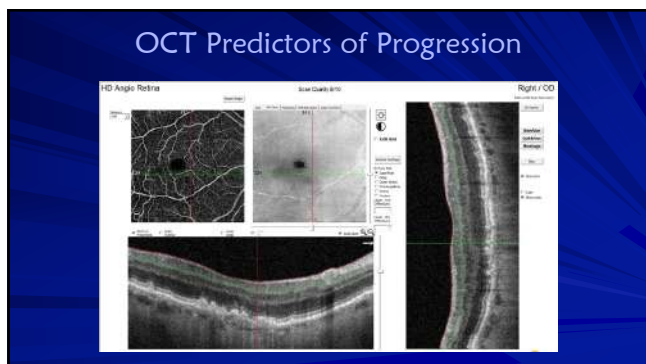
80



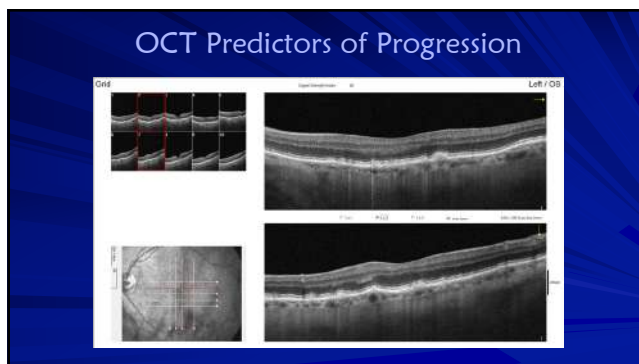
81



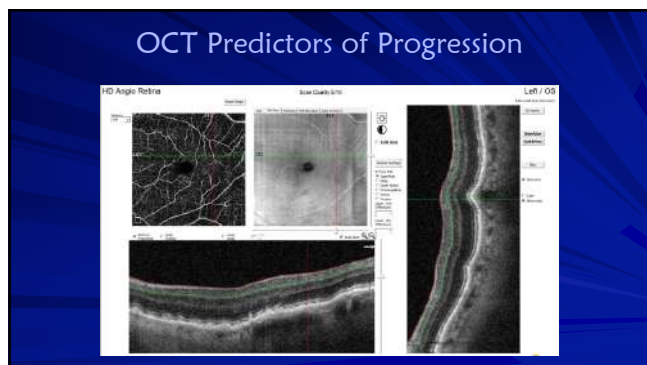
82



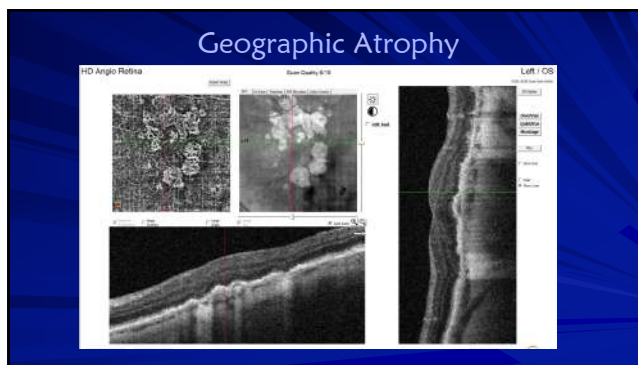
83



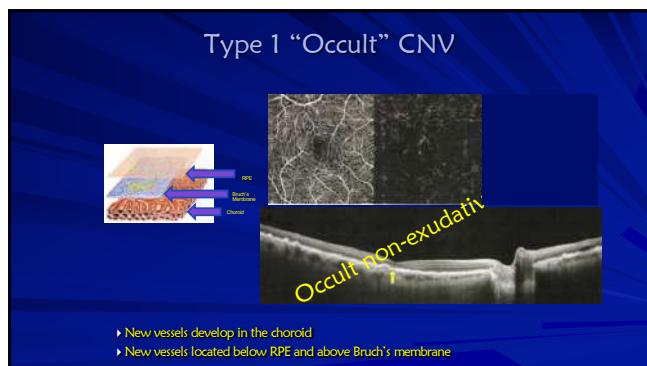
84



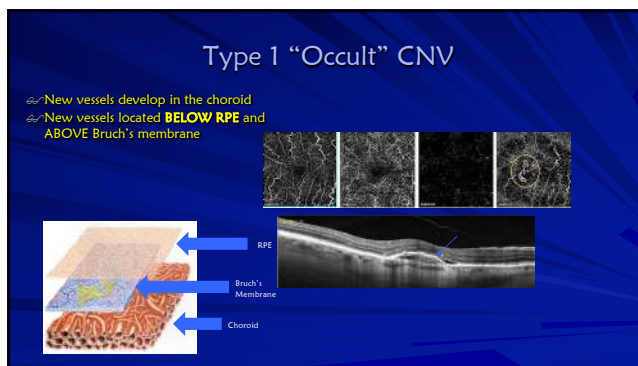
85



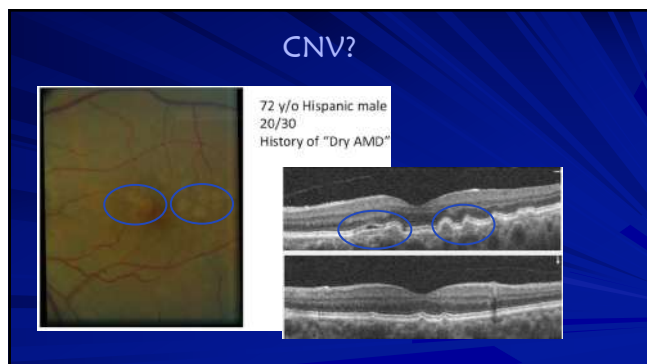
86



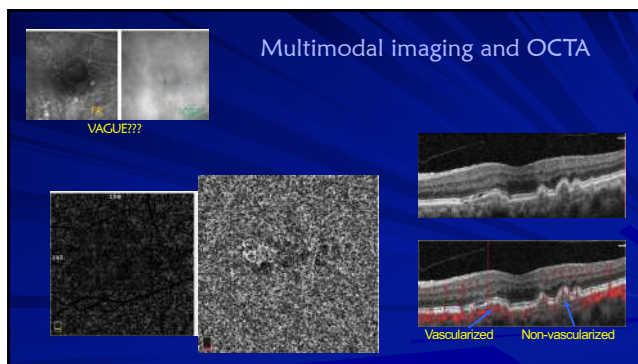
87



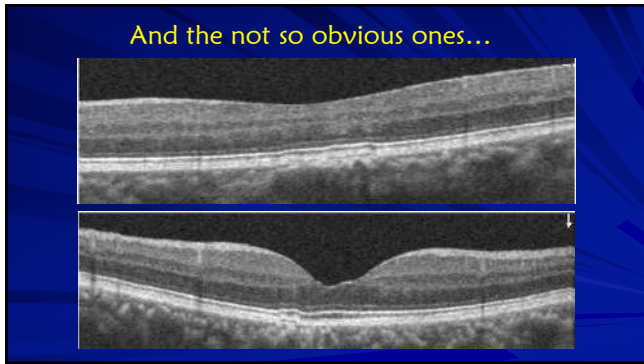
88



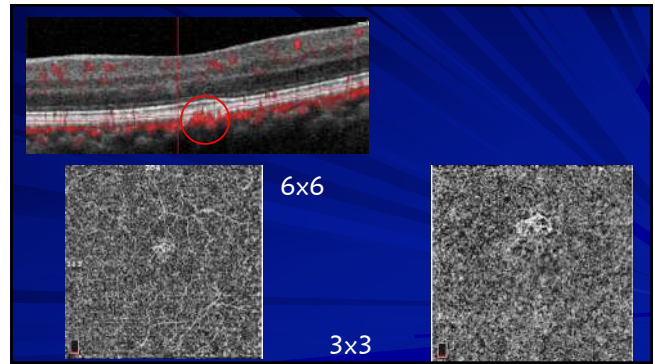
89



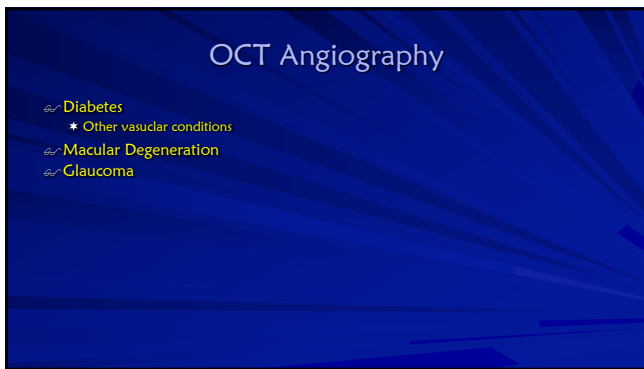
90



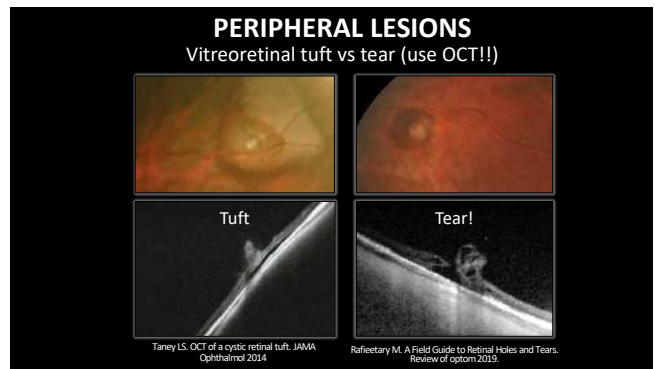
91



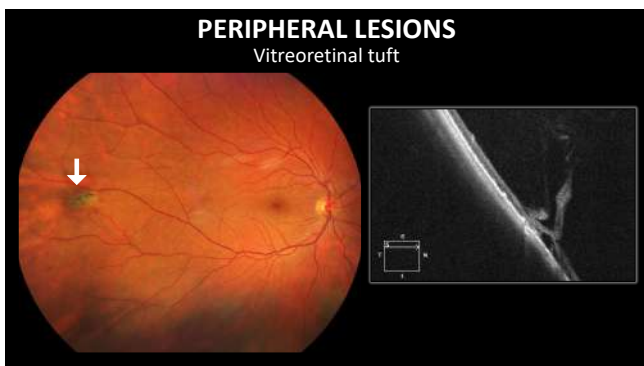
92



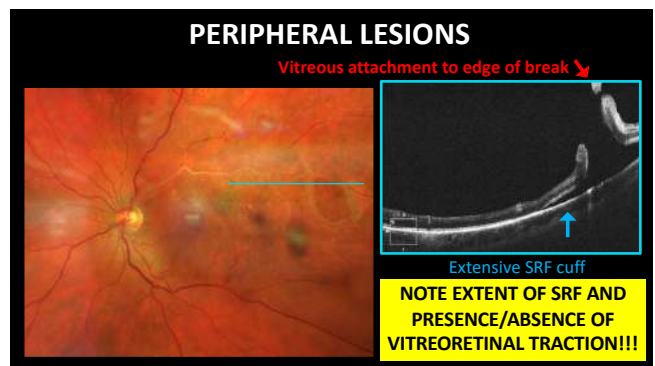
93



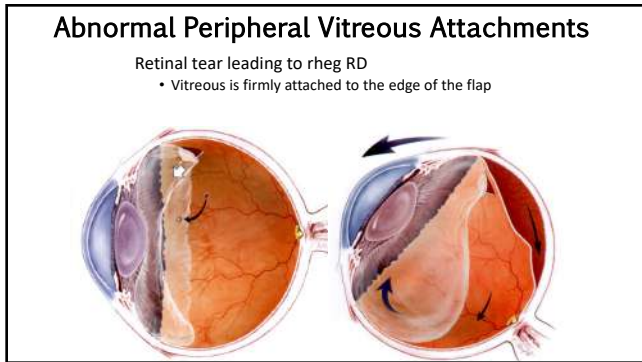
94



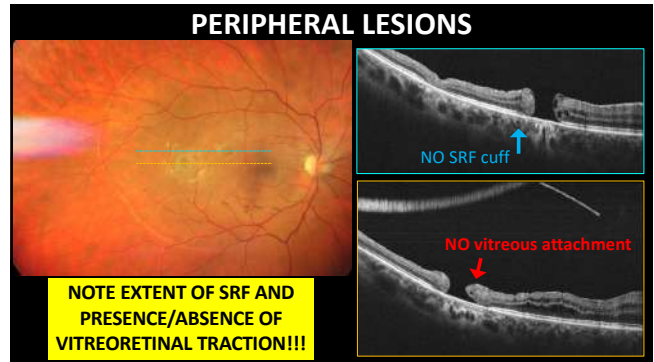
95



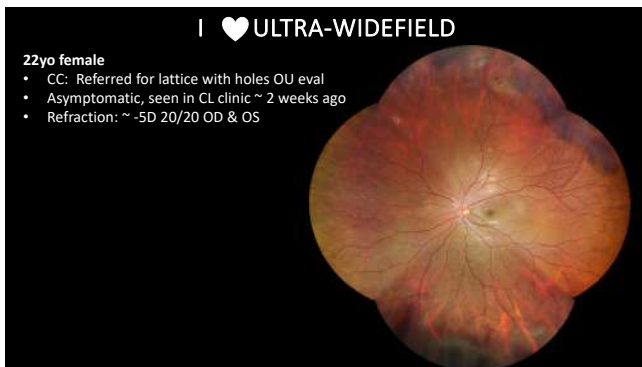
96



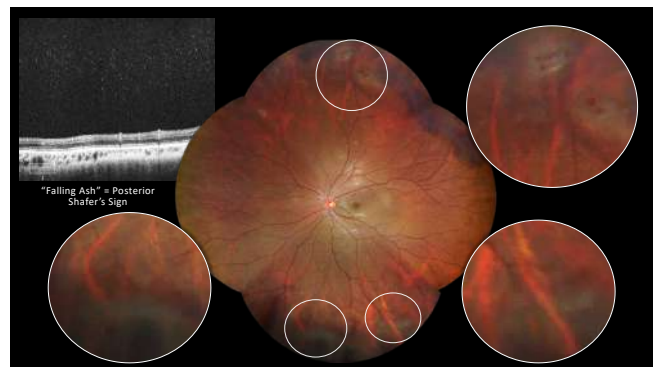
97



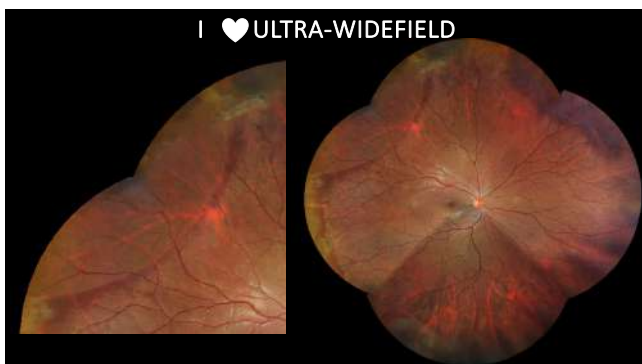98



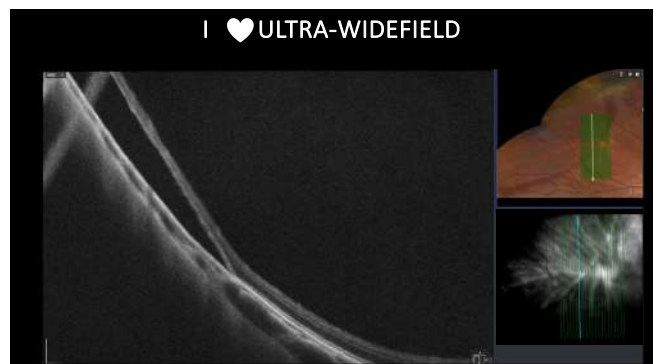99



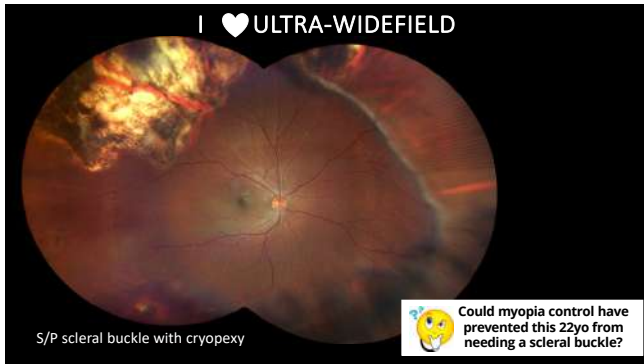
100



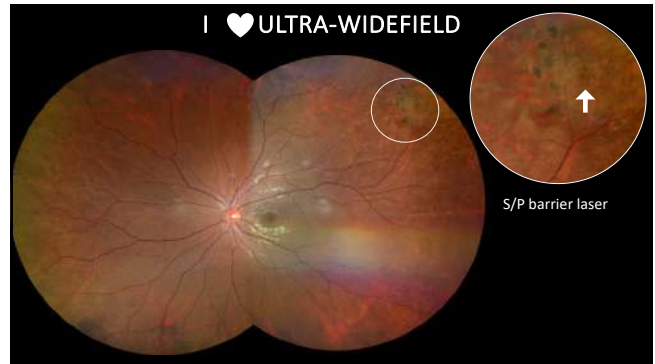
101



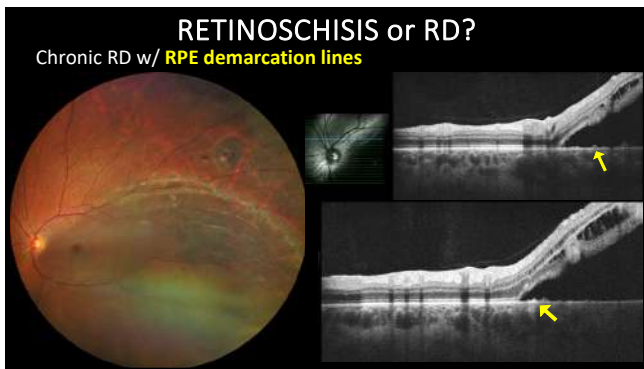
102



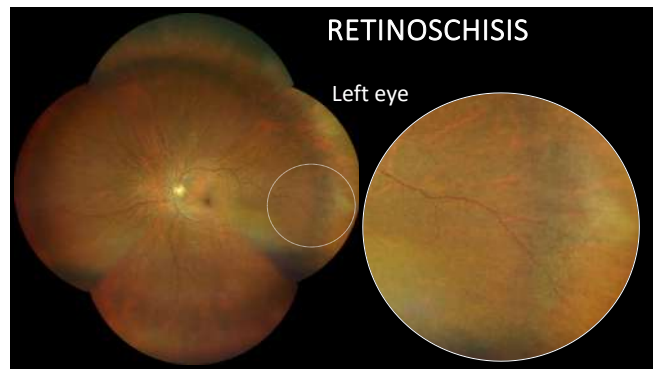
103



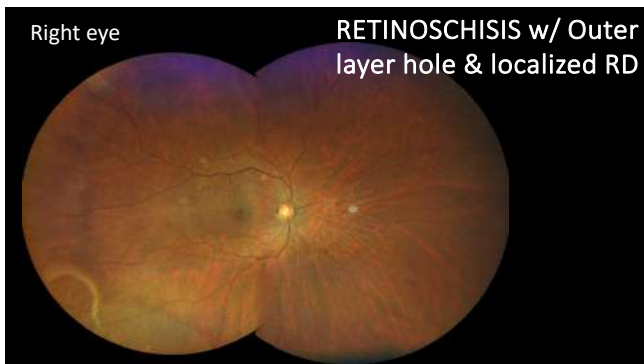
104



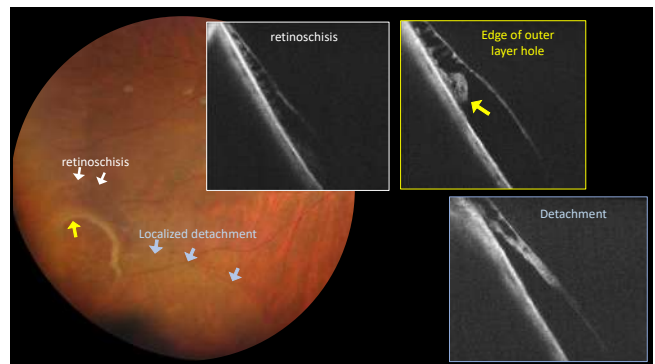
105



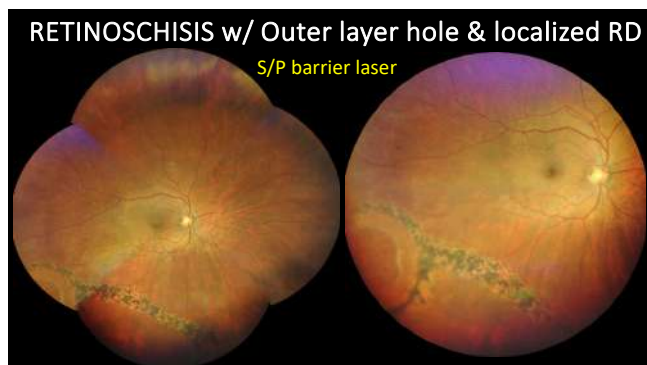
106



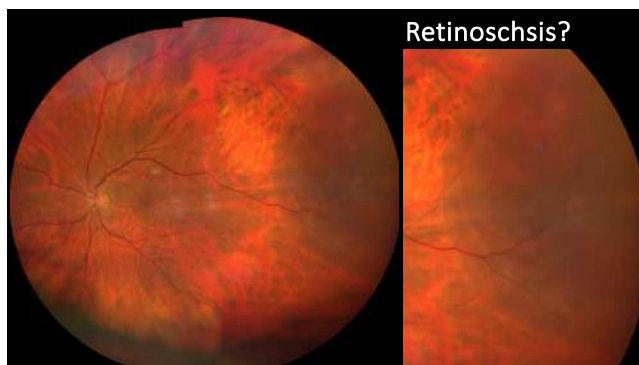
107



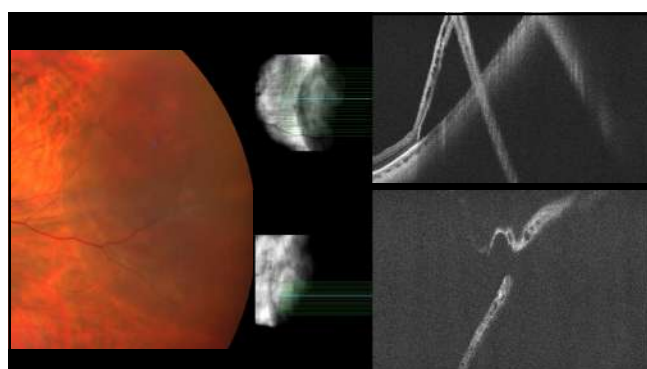
108



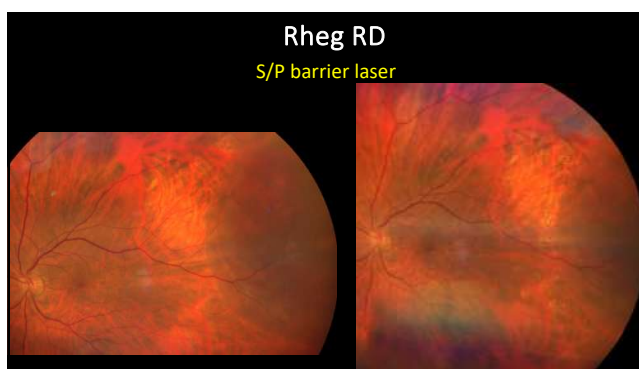
109



110



111



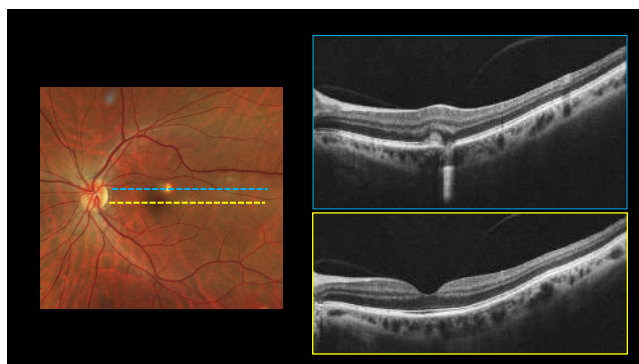
112

ACUTE ONSET METAMORPHOPSIA

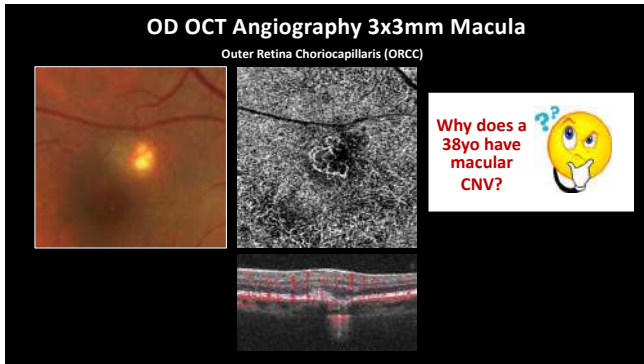
38yo Native American female

- CC: new onset floaters and slightly distorted vision OS x 3 days
- Oc Hx: LASIK OU 2010, pt reports there were "old scars" seen in the back of the eyes when she had LASIK done
- Med Hx: WNL
- BCVA :
 - OD: 20/20
 - OS: 20/25+2

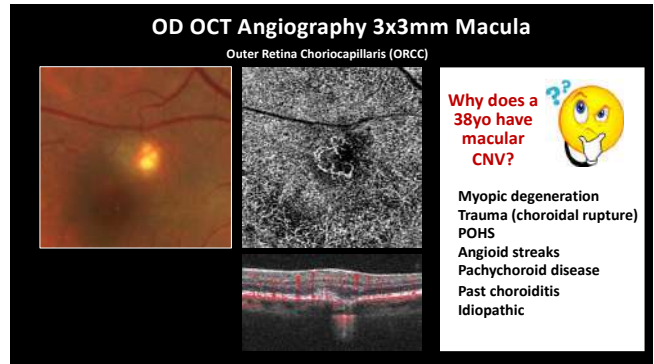
113



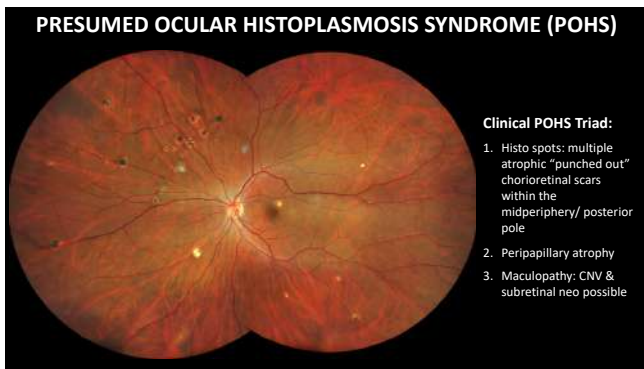
114



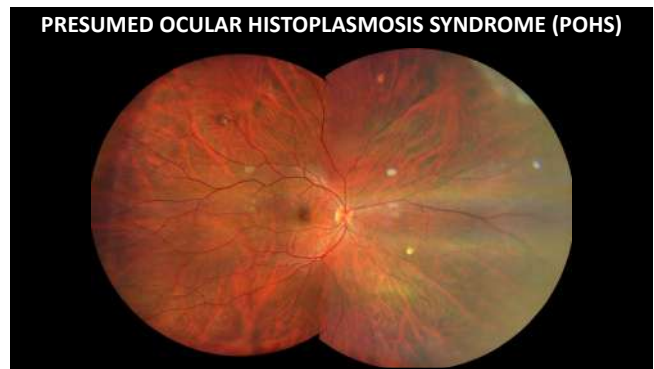
115



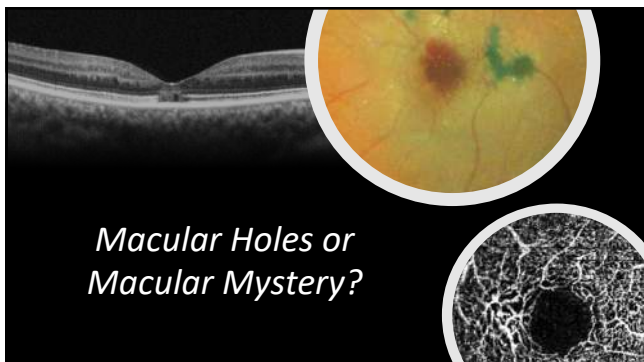116



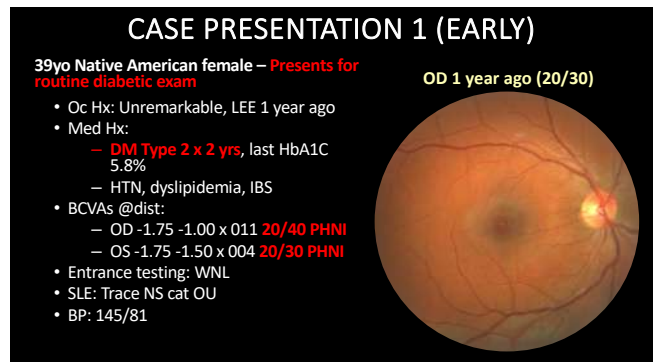
117



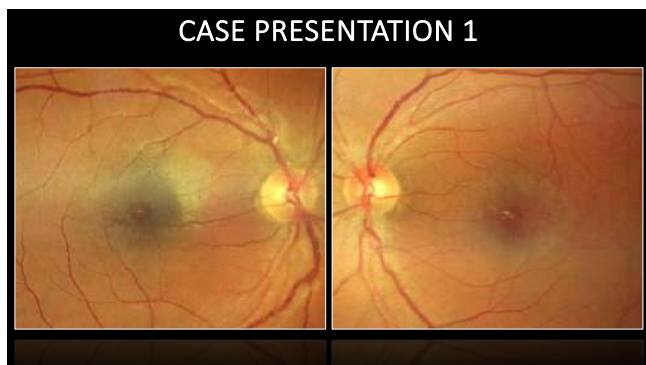
118



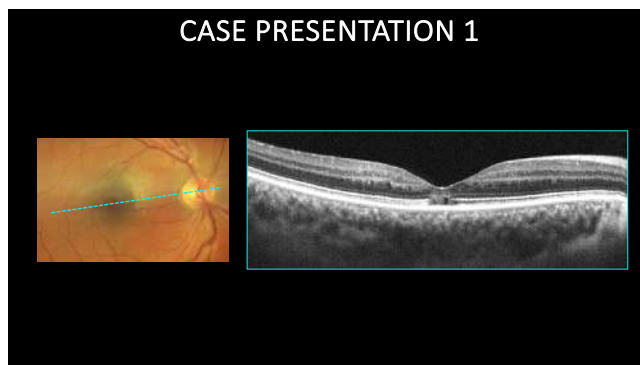119



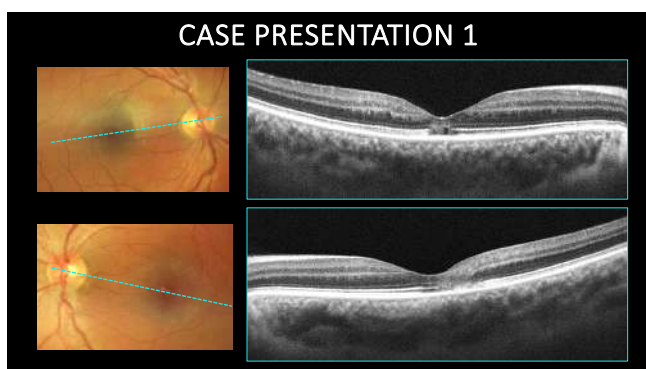
120



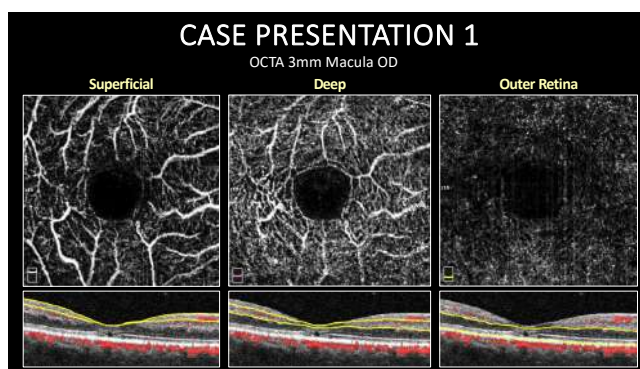
121



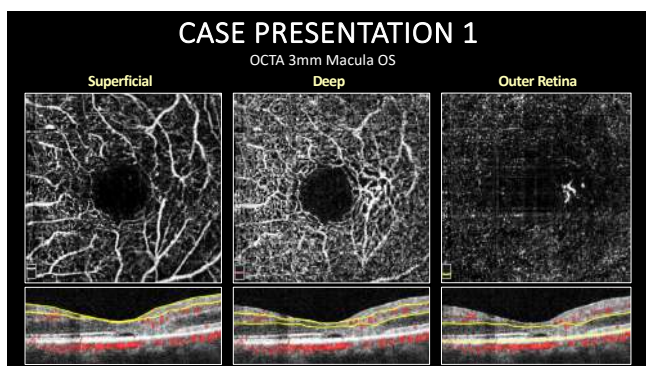
122



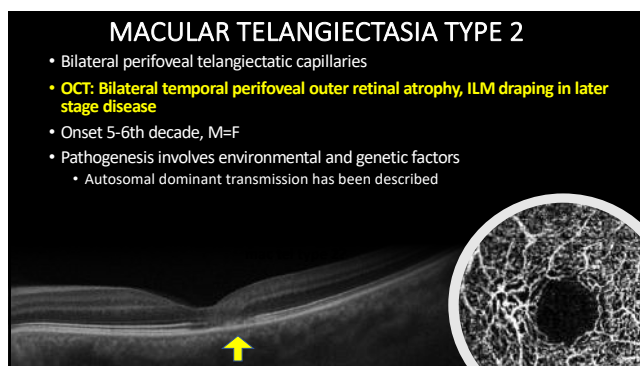
123



124



125



126

MACULAR TELANGIECTASIA TYPE 2

- CNTF FDA-approved tx for non-proliferative mac tel type 2
- For eyes with active SRN, intravitreal anti-VEGF therapy is usually instituted although high-quality guiding evidence is lacking
- May eventually be complicated by **full thickness macular hole (FTMH)** formation
- → refer FTMHs for consideration of surgical repair!

Kim, YH., et al. OCT features of mac tel type 2: Korean Macular Telangiectasia Type 2 Study—Report No. 1. Sci Rep 2020

127

CILINARY NEUROTROPHIC FACTOR (CNTF)

- ENCELTO (revakinagene taroretcel-lwey) FDA approved March 2025 to slow progression of macular telangiectasia type 2 (MacTel 2)
- Allogeneic encapsulated cell-based gene therapy (ECT), surgically implanted into the vitreous and sutured to the sclera in an outpatient procedure
- Sustained release of CNTF for up to 14 years, slow photoreceptor degeneration
- Phase III results: Rate of change in ellipsoid zone (EZ) area loss from baseline through 24 months 56.4% rate of reduction in Protocol A (p<0.0001) and 29.2 % rate of reduction in Protocol B (p=0.021)
- Ideal candidates?

128

Proliferative Mac Tel Type 2

57yo Hispanic female – Referred from primary care for possible macular dystrophy/macular scarring OU

- CC: gradually progressive vision loss OU x several years
- Oc Hx: No known illness or fam Hx. No prior surg or trauma.
- Med Hx: Unremarkable
- BCVAs @dist:
 - OD **20/100 PHNI**
 - OS **20/200 PHNI**
- Entrance testing: WNL
- SLE: 1-2+ NS cat OU

129

Proliferative Mac Tel Type 2

130

Proliferative Mac Tel Type 2

OCTA 3mm Macula OS

Superficial

Deep

Outer Retina (Custom)

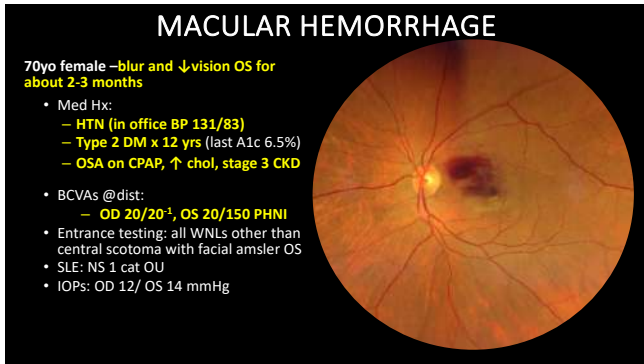
131

MACULAR TELANGIECTASIA TYPE 2

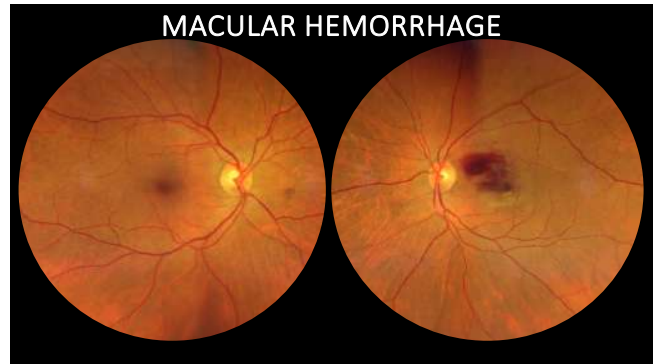
The "take home message"

- OCTA allows for earlier detection of perifoveal telangiectasia in early, subclinical mac tel type 2
- OCTA aids in the detection of subretinal neovascularization in mac tel type 2
- Mac tel type 2 eyes with active subretinal neovascularization should be referred for consideration of treatment
 - Better prognosis with earlier treatment and small size neo

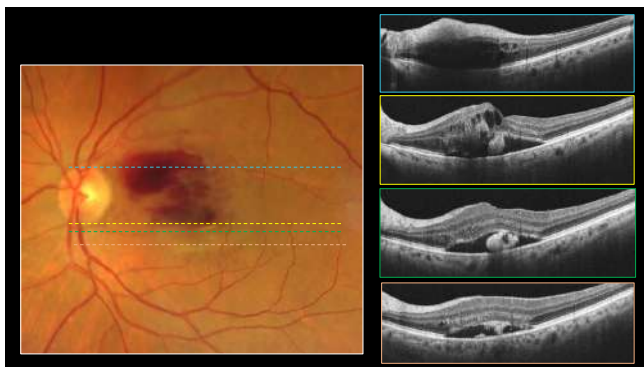
132



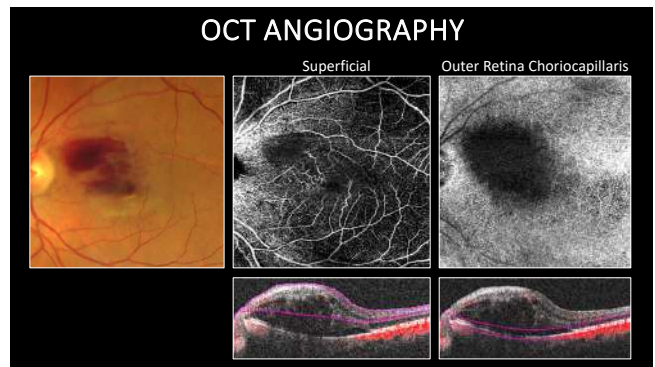
133



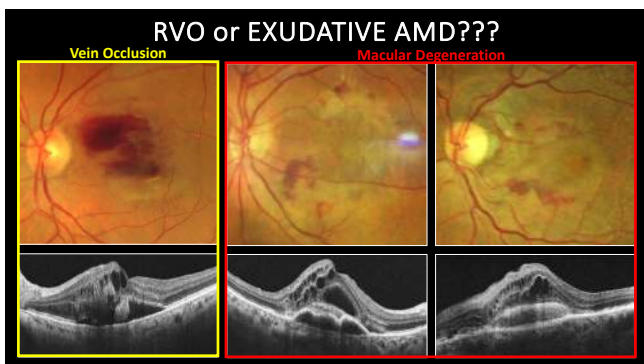
134



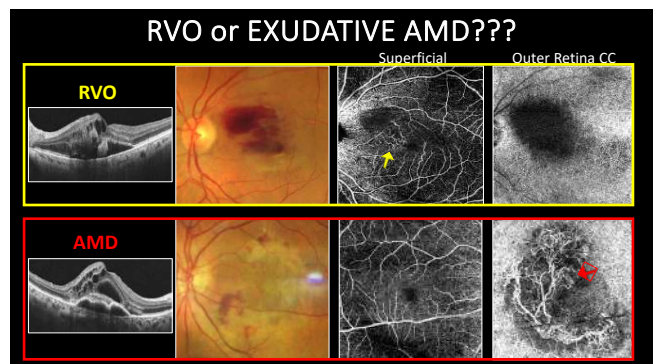
135



136

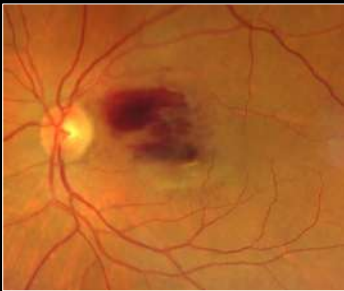


137



138

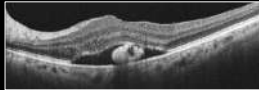
RVO or AMD??



Assessment: Twig/macular RVO with macular edema



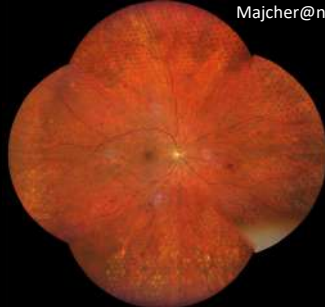
Plan:

- Refer to retina for anti-VEGF
- Communicate to PCP:
 - Importance of tight HTN, DM, and chol control as well as DC smoking to reduce the risk of fellow eye RVO
 - Higher risk of CVD and stroke
 - Change diuretics to other HTN meds if possible



139

THANK YOU!
Majcher@nsuok.edu




140

On behalf of Vision Expo, we sincerely thank you for being with us this year.

Reminder to Complete Your Session Evaluations!

Please be sure to complete your digital session evaluations for each course you attended! Your feedback is important to us as our Education Planning Committee considers content and speakers for future meetings to provide you with the best education possible.




141

Question and Thank You!

OCT and OCT Angiography
Real World Case Studies for Enhanced Interpretation

Greg Caldwell OD, FAAO
Carolyn Majcher, OD, FAAO
Vision Expo
Thursday, March 12, 2026



142